

## ORIGINAL ARTICLE

## White-matter microstructure and gray-matter volumes in adolescents with subthreshold bipolar symptoms

M-L Paillère Martinot<sup>1,2,3,4</sup>, H Lemaitre<sup>2,3,4</sup>, E Artiges<sup>2,3,4,5</sup>, R Miranda<sup>2,3,4</sup>, R Goodman<sup>6</sup>, J Penttilä<sup>7</sup>, M Struve<sup>8</sup>, T Faday<sup>9</sup>, V Kappel<sup>10</sup>, L Poustka<sup>11</sup>, P Conrod<sup>6,12</sup>, T Banaschewski<sup>11</sup>, A Barbot<sup>13</sup>, GJ Barker<sup>6</sup>, C Büchel<sup>9</sup>, H Flor<sup>8</sup>, J Gallinat<sup>14</sup>, H Garavan<sup>15,16</sup>, A Heinz<sup>14</sup>, B Ittermann<sup>17</sup>, C Lawrence<sup>18</sup>, E Loth<sup>6,19</sup>, K Mann<sup>8</sup>, T Paus<sup>18,20,21</sup>, Z Pausova<sup>22</sup>, M Rietschel<sup>8</sup>, TW Robbins<sup>23</sup>, MN Smolka<sup>24,25</sup>, G Schumann<sup>6,19</sup>, J-L Martinot<sup>2,3,4</sup> and the IMAGEN consortium (www.imagen-europe.com)<sup>26</sup>

Abnormalities in white-matter (WM) microstructure, as lower fractional anisotropy (FA), have been reported in adolescent-onset bipolar disorder and in youth at familial risk for bipolarity. We sought to determine whether healthy adolescents with subthreshold bipolar symptoms (SBP) would have early WM microstructural alterations and whether those alterations would be associated with differences in gray-matter (GM) volumes. Forty-two adolescents with three core manic symptoms and no psychiatric diagnosis, and 126 adolescents matched by age and sex, with no psychiatric diagnosis or symptoms, were identified after screening the IMAGEN database of 2223 young adolescents recruited from the general population. After image quality control, voxel-wise statistics were performed on the diffusion parameters using tract-based spatial statistics in 25 SBP adolescents and 77 controls, and on GM and WM images using voxel-based morphometry in 30 SBP adolescents and 106 controls. As compared with healthy controls, adolescents with SBP displayed lower FA values in a number of WM tracts, particularly in the corpus callosum, cingulum, bilateral superior and inferior longitudinal fasciculi, uncinate fasciculi and corticospinal tracts. Radial diffusivity was mainly higher in posterior parts of bilateral superior and inferior longitudinal fasciculi, inferior fronto-occipital fasciculi and right cingulum. As compared with controls, SBP adolescents had lower GM volume in the left anterior cingulate region. This is the first study to investigate WM microstructure and GM morphometric variations in adolescents with SBP. The widespread FA alterations in association and projection tracts, associated with GM changes in regions involved in mood disorders, suggest altered structural connectivity in those adolescents.

*Molecular Psychiatry* (2014) **19**, 462–470; doi:10.1038/mp.2013.44; published online 30 April 2013

**Keywords:** adolescence; diffusion tensor imaging; gray matter; magnetic resonance imaging; subthreshold bipolar disorder; white matter

## INTRODUCTION

Emotional instability is frequent in adolescence and experiencing hypomanic symptoms is a common adolescent phenomenon that is generally transient<sup>1</sup> and might represent a developmental stage.<sup>2</sup> This emotional instability may be marked and considered as subthreshold bipolarity (SBP) and vulnerability to mood disorders.<sup>3,4</sup> Lifetime prevalence of SBP has been found to be 5.7%,<sup>5</sup> and a significant proportion (36–45%) of adolescents having SBP symptoms have been found to escalate to bipolar disorder (BD),<sup>6,7</sup> particularly when symptom load increases.<sup>8</sup>

Outcomes in full-syndrome depressive and anxiety disorders in young adulthood have also been reported.<sup>9</sup>

Recent evidence indicates that early white-matter (WM) abnormalities may have a significant part in the pathophysiology of BD, and represent an early marker of the disorder.<sup>10–12</sup> Indeed, WM alterations denoted by lower fractional anisotropy (FA), a measure of water diffusion reflecting WM bundles' coherence, have been reported in medication-naïve adolescents with BD,<sup>11</sup> or in pediatric samples involving adolescents.<sup>10</sup> However, studies of very early stages of the disease, or studies of vulnerable

<sup>1</sup>AP-HP, Department of Adolescent Psychopathology and Medicine, Maison de Solenn, Cochin Hospital, Paris, France; <sup>2</sup>Université Paris Descartes, Sorbonne Paris Cité, Paris, France; <sup>3</sup>INSERM, UMR 1000, Research unit Imaging and Psychiatry, IFR49, CEA, DSV, I<sup>2</sup>BM-Service Hospitalier Frédéric Joliot, Orsay, France; <sup>4</sup>Université Paris-Sud 11, Orsay, France; <sup>5</sup>Psychiatry Department 91G16, Orsay Hospital, Orsay, France; <sup>6</sup>Institute of Psychiatry, King's College London, London, UK; <sup>7</sup>University of Tampere, School of Medicine, Tampere, Finland; <sup>8</sup>Department of Cognitive and Clinical Neuroscience, Central Institute of Mental Health, Medical Faculty Mannheim/Heidelberg University, Mannheim, Germany; <sup>9</sup>Universitaetsklinikum Hamburg Eppendorf, Hamburg, Germany; <sup>10</sup>Department of Child and Adolescent Psychiatry, Psychosomatics and Psychotherapy, Charité-Universitätsmedizin, Berlin, Germany; <sup>11</sup>Department of Child and Adolescent Psychiatry and Psychotherapy, Central Institute of Mental Health, Medical Faculty Mannheim/Heidelberg University, Mannheim, Germany; <sup>12</sup>Department of Psychiatry, Université de Montréal, CHU Ste Justine Hospital, Montréal, QC, Canada; <sup>13</sup>Neurospin, Commissariat à l'Énergie Atomique et aux Énergies Alternatives, Paris, France; <sup>14</sup>Department of Psychiatry and Psychotherapy, Charité—Universitätsmedizin, Berlin, Germany; <sup>15</sup>Institute of Neuroscience, Trinity College Dublin, Dublin, Ireland; <sup>16</sup>Departments of Psychiatry and Psychology, University of Vermont, Burlington, VT, USA; <sup>17</sup>Physikalisch-Technische Bundesanstalt (PTB), Braunschweig und Berlin, Germany; <sup>18</sup>School of Psychology, University of Nottingham, Nottingham, UK; <sup>19</sup>MRC Social, Genetic and Developmental Psychiatry (SGDP) Centre, London, UK; <sup>20</sup>Rotman Research Institute, University of Toronto, Toronto, ON, Canada; <sup>21</sup>Montreal Neurological Institute, McGill University, Toronto, QC, Canada; <sup>22</sup>Department of Physiology and Nutritional Sciences, The Hospital for Sick Children, University of Toronto, Toronto, ON, Canada; <sup>23</sup>Behavioural and Clinical Neuroscience Institute and Department of Psychology, University of Cambridge, Cambridge, UK; <sup>24</sup>Department of Psychiatry and Psychotherapy, Technische Universität Dresden, Dresden, Germany and <sup>25</sup>Neuroimaging Center, Department of Psychology, Technische Universität Dresden, Dresden, Germany. Correspondence: Dr M-L Paillère Martinot, Maison de Solenn, APHP, Hôpital Cochin, 97 Boulevard de Port-Royal, 75014 Paris, France.  
E-mail: ml.paillere@cch.aphp.fr

<sup>26</sup>See Appendix.

subjects are scarce. A few diffusion tensor imaging (DTI) studies have investigated youth at *familial* risk for BD or depression, either healthy<sup>13,14</sup> or having comorbidities.<sup>15</sup> Those studies have observed decreased FA in major WM tracts such as the cingulum, the corpus callosum, the uncinate fasciculus or the superior longitudinal fasciculus,<sup>10,14,15</sup> one of these studies has suggested altered WM maturation during adolescence.<sup>13</sup>

In addition, BD and depression in adolescents have been variously associated with gray-matter (GM) reductions in prefrontal and cingulate cortices, and in the amygdala–hippocampus complex.<sup>16–24</sup> Increased GM volume of the left superior temporal cortex has also been observed in BD adolescents.<sup>24</sup>

Although SBP might represent a very early stage of—or a vulnerability predisposition to—bipolar, depressive or anxiety disorders, so far no study has investigated brain correlates in adolescents displaying SBP symptoms. Thus, it is unknown whether such emotional instability in adolescents is associated with variations in the maturation of WM and GM.

We hypothesized that adolescents with SBP symptoms might exhibit differences in WM bundles and in brain regions implicated in mood disorders, such as frontal–limbic networks. We sought to investigate WM microstructure using DTI, and GM and WM volumes using T1-weighted magnetic resonance imaging in healthy adolescents with SBP symptoms. To this end, we used the IMAGEN database, a European database constituted across eight study centers in France, United Kingdom, Ireland and Germany, which includes 2223 adolescents recruited in middle schools around age 14 years.<sup>25</sup>

## PARTICIPANTS AND METHODS

The investigation was performed in accordance with the Declaration of Helsinki. The study was approved by the ethics committees in all participating institutions. Written informed assent and consent were obtained, respectively, from all adolescents and their parents after complete description of the study.

A detailed description of recruitment and assessment procedures, and exclusion and inclusion criteria has been published.<sup>25</sup>

### Participants

After screening of the IMAGEN database, 42 adolescents with SBP symptoms and 126 controls were found eligible for this study. Clinical symptoms were self-reported by the participants using the Development and Well-Being Assessment (DAWBA),<sup>26</sup> a computerized self-report assessment that generates diagnoses based on the DSM-IV (Statistical Manual of Mental Disorders, Fourth Edition) and on the ICD-10 (10th revision of the International Statistical Classification of Diseases), subsequently validated by a group of trained raters from IMAGEN consortium psychiatrists and psychologists. In the DAWBA, presence of symptoms is rated as ‘no’, ‘a little’ or ‘a lot’.

Subthreshold bipolarity was defined as a distinct period of abnormally and persistently elevated, expansive or irritable mood associated with one or more manic or hypomanic symptoms in number and duration below criteria threshold to qualify for a diagnosis of bipolar episode.<sup>3</sup> The *SBP group* was constituted by those adolescents who had no identified diagnosis on any diagnostic categories and rated ‘a lot’ on at least one cardinal manic symptom (‘expansive mood’ or ‘unstable mood’) and on at least ‘accelerated speech’ and ‘decreased sleep’ using the adolescent DAWBA symptom assessment ([www.dawba.info/Bipolar](http://www.dawba.info/Bipolar)). These criteria included two out of three core symptoms for the diagnosis of mania,<sup>27,28</sup> expansive mood and pressure of speech that have been reported in 82% of subthreshold mania cases.<sup>29</sup> In addition, we chose the ‘decreased need for sleep’ item that has been found in 94% of cases of mania<sup>30</sup> and in 57% of subthreshold cases.<sup>29</sup> We discarded the hyperactivity symptom of mania, as it has been reported to overlap with attention deficit-hyperactivity disorder.<sup>31</sup> The participants’ distribution did not differ across centers (Table 1).

The control adolescents were selected using the DAWBA-generated probability levels of having a psychiatric diagnosis. We chose the adolescents whose probabilities to have any diagnosis was no more than 0.5%, who had no validated diagnosis, no depressive symptoms and

whose rating of the selected manic symptoms was ‘no’ or ‘a little’. They were ‘matched’ for age and sex to the SBP group using a ‘genetic search algorithm’.<sup>32</sup>

The psychometric characterization was partly conducted in participants’ homes using the Psytools software (Delosis, London, UK). Self-ratings were retrieved for substance use (Alcohol Use Disorders Identification Test; European School Survey Project on Alcohol and Drugs),<sup>33,34</sup> and emotion and behavior (Strengths and Difficulties Questionnaire (SDQ)).<sup>35</sup>

Five participants in the SBP group, and two in the control group reported alcohol abuse, and one SBP adolescent and no control reported cannabis dependence.

In addition, the adolescents were assessed with five subtests of the Wechsler Intelligence Scale for Children (WISC-IV) to estimate intelligence quotient.

Puberty status was self-assessed using the computerized Pubertal Development Status (PDS) questionnaire,<sup>36</sup> and family history of mood disorders was assessed with the Family Interview for Genetic Studies (National Institute of Mental Health, Bethesda, MD, USA).<sup>25</sup>

Eight participants in the SBP group (19%) and 26 in the control group (21%) reported either history of depression (recurrent or single episode) or history of BD in first- or second-degree relatives ( $\chi^2$  test = 0, d.f. = 1,  $P = 0.99$ ).

### Magnetic resonance imaging data acquisition

T1-weighted and diffusion tensor images were obtained on 3T scanners from a range of manufacturers (Siemens, Munich, Germany; Philips, Best, The Netherlands; General Electrics, Chalfont St Giles, UK; Bruker, Ettlingen, Germany). The imaging protocols comparability in the different scanners was through a thorough standardization.<sup>25</sup> All participants were instructed to close their eyes and keep as immobile as possible during image acquisition.

High-resolution T1-weighted images were acquired using a Magnetization Prepared Rapid Acquisition Gradient Echo sequence based on the ADNI protocol (<http://www.loni.ucla.edu/ADNI/Cores/index.shtml>). Scanning parameters were similar in all centers (sagittal slice plane; repetition time = 2300 ms; echo time = 2.8 ms; flip angle = 8°; 256 × 256 × 160 matrix; voxel size: 1.1 × 1.1 × 1.1 mm). The diffusion tensor images were acquired using an Echo Planar imaging sequence (4  $b = 0$  and 32 directions with  $b$ -value = 1300 s/mm<sup>2</sup>; axial slice plane; echo time = 104 ms; 128 × 128 × 60 matrix; voxel size 2.4 × 2.4 × 2.4 mm), adapted to tensor measurements (for example, FA, mean diffusivity (MD)) and tractography analysis.

### Preprocessing of T1-weighted magnetic resonance imaging data

T1-weighted image preprocessing and analysis were performed with Statistical Parametric Mapping 8 software package (SPM8; Wellcome Department of Cognitive Neurology, London, UK; [www.fil.ion.ucl.ac.uk/spm](http://www.fil.ion.ucl.ac.uk/spm)). Study-specific adolescent brain tissue templates (Tissue Probability Maps) were created from a subsample of 240 adolescents randomly drawn from the IMAGEN database (15 girls and 15 boys from each center, comparable for age) to take into account the age specificity of our sample. All IMAGEN T1-weighted images were then segmented using our customized Tissue Probability Maps and the unified segmentation model<sup>37</sup> included in the new segment toolbox. The unified segmentation enables bias correction, spatial normalization and tissue segmentation into GM, WM and cerebrospinal fluid within the same generative model. Segmented images were modulated to preserve participant’s original tissue quantity after spatial normalization and resliced to 1.5 × 1.5 × 1.5 mm. Finally, the normalized, segmented and modulated GM images were smoothed using a Gaussian kernel of 10-mm full-width at half-maximum.

### Preprocessing of diffusion data

Diffusion data preprocessing was performed using FMRIB Diffusion Toolbox in the FSL software ([www.fmrib.ox.ac.uk/fsl](http://www.fmrib.ox.ac.uk/fsl)) and consisted of affine registration to the first  $b = 0$  image for head motion and eddy currents correction, brain extraction using the Brain Extraction Tool (BET),<sup>38</sup> and diffusion tensor fitting to obtain FA, MD, axial diffusivity (AD) and radial diffusivity (RD) images. Voxel-wise statistical analysis of the FA data was carried out using tract-based spatial statistics (TBSS) part of FSL.<sup>39</sup> All participants’ FA data were aligned into a common space using the nonlinear registration tool FNIRT,<sup>40,41</sup> which uses a  $b$ -spline representation of the registration warp field.<sup>42</sup> Next, the mean FA image was created and thinned to create a mean FA skeleton, which represents the

**Table 1.** Demographic, clinical and imaging characteristics in adolescents with subthreshold bipolar symptoms compared with controls

Subjects' characteristics	Subthreshold bipolars (n = 42)	Controls (n = 126)	Test $\chi^2(7, N = 168)$	P-value
Subjects (%) in each center <sup>a</sup>	11.9, 9.5, 2.3, 16.6, 14.3, 14.3, 14.2, 16.6	7.1, 15.8, 11.1, 12.6, 11.1, 15.8, 9.5, 16.6	5.78	0.56
Gender (females/males)	27/15	77/49	0.03	0.85
Handedness (% right)	87.50	89.43	0.002	0.96
	Mean (s.d.)	Mean (s.d.)	t(166)	
Age (years)	14.58 (0.44)	14.56 (0.39)	0.27	0.78
PDS score	3.20 (0.43)	2.95 (0.59)	2.43	0.02
IQ score	109 (13)	107 (11)	0.48	0.63
SDQ: Total difficulties score	13.50 (5.37)	7.89 (3.91)	7.28	$1.26 \times 10^{-5}$
SDQ: Emotional symptoms score	3.11 (2.53)	1.92 (1.55)	3.64	$3.59 \times 10^{-4}$
SDQ: Conduct problems score	3.16 (1.83)	1.29 (1.18)	7.66	$1.40 \times 10^{-12}$
SDQ: Hyperactivity score	5.30 (2.60)	3.33 (1.90)	5.27	$4.03 \times 10^{-7}$
SDQ: Peer problems score	1.90 (1.70)	1.34 (1.43)	2.07	0.04
SDQ: Prosocial score	7.45 (1.72)	8.04 (1.41)	2.23	0.03
SDQ: Impact score	0.90 (1.35)	0.05 (0.29)	6.61	$4.94 \times 10^{-10}$
	Subthreshold bipolars (n = 30) Mean (s.d.)	Controls (n = 106) Mean (s.d.)	F(1,131)	
TIV (cm <sup>3</sup> ) <sup>b</sup>	1559.20 (120.50)	1583.50 (130.70)	0.003	0.95
Gray matter (% of TIV) <sup>b</sup>	46.40 (1.40)	47.30 (1.20)	6.77	0.01
White matter (% of TIV) <sup>b</sup>	29.50 (1.30)	29.90 (1.00)	0.91	0.33
Cerebrospinal fluid (% of TIV) <sup>b</sup>	23.90 (2.20)	22.70 (1.80)	5.26	0.02
	Subthreshold bipolars (n = 25) Mean (s.d.)	Controls (n = 77) Mean (s.d.)	F(1,96)	
Mean diffusivity <sup>b,c</sup>	0.727 (0.025)	0.726 (0.017)	0.45	0.50
Fractional anisotropy <sup>b</sup>	0.438 (0.020)	0.442 (0.019)	6.09	0.02
Axial diffusivity <sup>b,c</sup>	1.104 (0.034)	1.109 (0.027)	0.74	0.39
Radial diffusivity <sup>b,c</sup>	0.538 (0.025)	0.534 (0.019)	2.31	0.13

Abbreviations: IQ, intelligence quotient; PDS, pubertal development score; SDQ, Strengths and Difficulties Questionnaire; TIV, total intracranial volume.

<sup>a</sup>London, Nottingham, Dublin, Berlin, Hamburg, Mannheim, Paris and Dresden, respectively.

<sup>b</sup>Controlled for PDS and scanner or acquisition types. <sup>c</sup>Value  $\times 10^3$ .

centers of all tracts common to the group. This skeleton was then thresholded to  $FA > 0.2$  to keep only the main tracts. Each adolescent's aligned FA, MD, AD and RD data were then projected onto this skeleton and the resulting data fed into voxel-wise cross-individual statistics.

#### Data quality control

Images were reconstructed and visually checked for major artifacts before additional processing. Eleven SBP and 19 control T1-weighted datasets were discarded because of low signal-to-noise ratio, motion artifacts and blink eye artifacts. Twelve SBP and 33 control DTI datasets were discarded because of head movement and poor tensor computation. After voxel-based morphometry preprocessing, one control T1-weighted dataset was discarded because of poor spatial normalization. After TBSS preprocessing, 4 SBP and 16 control DTI datasets were discarded because of poor spatial normalization. Finally, one SBP participant was discarded because of missing PDS assessment. Thus, 30 SBP adolescents and 106 controls were available for voxel-based morphometry, and 25 SBP and 77 controls were available for TBSS analysis.

#### Statistical analyses

**Demographic and clinical data.** Analyses were performed using R software (<http://www.r-project.org/>). Unpaired *t*-tests, analyses of covariance and  $\chi^2$  tests were used for comparing continuous and categorical variables in between-group comparisons. Statistical significance was defined as  $P < 0.05$ , two-tailed.

**T1-weighted image analysis.** Voxel-wise comparisons were performed using SPM8 within the framework of the general linear model. GM results were obtained within a frontal-limbic mask adapted from Nugent and co-workers,<sup>43</sup> drawn using Wake Forest University PickAtlas,<sup>44</sup> and including the cingulate, orbital, medial prefrontal and superior temporal cortices. Brain locations were reported as *x*, *y* and *z* coordinates in Montreal Neurologic Institute space. Between-group comparisons of T1-weighted images were performed on GM and WM tissues using a two-sample *t*-test with PDS, scanner type and total intracranial volume (TIV) as confounding covariates. Significance threshold was set at  $P < 0.05$ , family-wise error corrected for multiple comparisons.

**DTI data analysis.** Voxel-wise group comparisons on FA, RD, AD and MD maps were tested in the framework of the general linear model using a randomization-based method (5000 permutations). We included PDS and DTI acquisition type as confounding covariates. Statistical thresholds were set at  $P < 0.05$  family-wise error corrected and threshold-free cluster enhancement corrected. The ICBM-DTI-81 WM labels atlas<sup>45</sup> and the JHU tractography atlas<sup>46</sup> were used within FSLView to locate the tracts that displayed significant differences between groups.

#### RESULTS

The SBP participants had higher scores than the controls regarding pubertal status and all difficulties scores retrieved using the SDQ, particularly the total impact scale score that reflects overall social impairment.<sup>47</sup> No other clinical difference was found between groups (Table 1).

**Table 2.** Differences in gray-matter volumes between subthreshold bipolar and healthy adolescents

Brain regions of lower gray-matter in subthreshold bipolars	BA	Cluster size <sup>a</sup>	MNI coordinates <sup>b</sup>			T-test <sup>c</sup>	pFWE-corr <sup>d</sup>
			x	y	z		
Left ACC	32	<b>1339</b>	-12	39	13	4.77	<b>0.008</b>
Left MedFG (gyrus rectus)	10	—	-3	58	13	4.16	0.068
Left MedFG	9	—	-2	48	19	3.99	0.117
Left ACC	24	52	-16	-18	42	3.70	0.261
Left PCC/precuneus	31	312	-18	-39	40	4.09	0.087
Left PCC	23	80	-15	-54	15	3.39	0.523
Left PCC/precuneus	31	—	-14	-69	15	3.37	0.547
Right ACC	24	87	16	-21	36	3.78	0.216
Right PCC/precuneus	31	203	16	-49	18	4.06	0.093
Right PCC	31	—	21	-60	13	3.42	0.496
Left STG	22	138	-60	-37	7	3.66	0.291

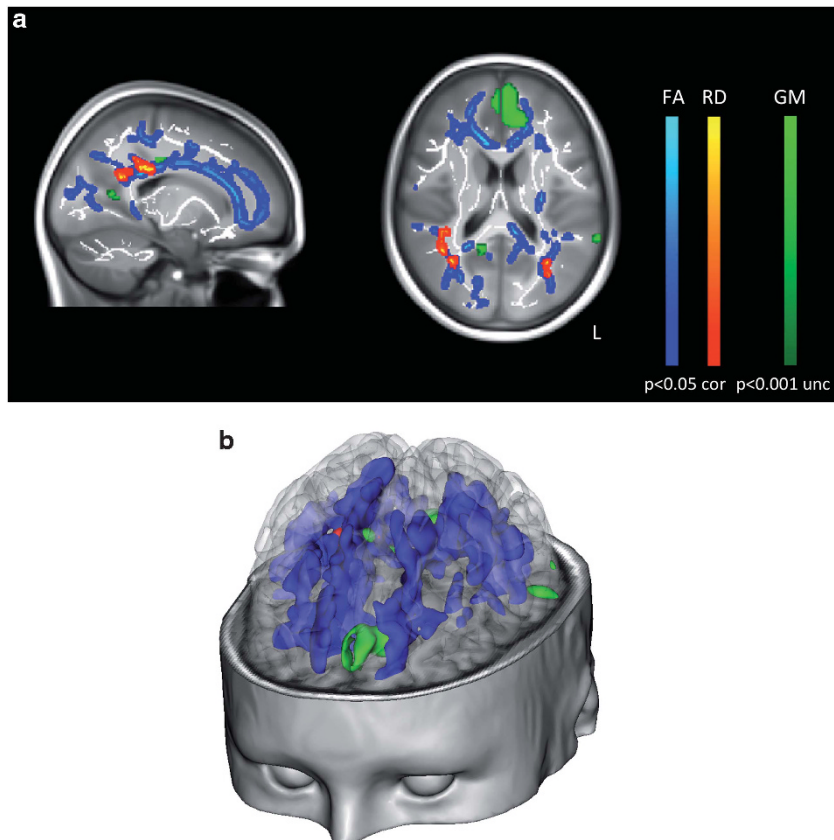
Abbreviations: ACC, anterior cingulate cortex; BA, Brodmann's area; MedFG, medial frontal gyrus; PCC, posterior cingulate cortex; STG, superior temporal gyrus; —, indicate that the region is included in the same cluster as the region immediately above.

<sup>a</sup>Cluster size is expressed in number of voxels, with voxel size = 3.375 mm<sup>3</sup>.

<sup>b</sup>Montreal Neurological Institute coordinates in millimeters.

<sup>c</sup>Statistics at voxel-level set to a minimum uncorrected threshold of  $P < 0.001$ , with height threshold  $T = 3.15$ , and extent threshold  $k = 10$  voxels.

<sup>d</sup> $P$ -value family-wise error-corrected for multiple comparisons; bold figures indicate significant results at  $P < 0.05$ .



**Figure 1.** (a) Top, sagittal and axial views:  $T$ -maps of comparisons between subthreshold bipolar (SBP) adolescents and controls superimposed on the average T1-weighted magnetic resonance imaging (MRI) of all IMAGEN database participants. Blue colour indicates white-matter tracts where fractional anisotropy (FA) is lower; red indicates tracts where radial diffusivity (RD) is higher ( $P < 0.05$  family-wise error corrected) in SBP adolescents; green indicates regions with lower gray-matter volume in SBP adolescents ( $P < 0.001$ , uncorrected); white indicates white-matter skeleton. FA and RD images are displayed using the 'tbs\_fill' script, which allows better visualization of the regions with significant between-group differences. (b) Three-dimensional representation using the Anatomist software (<http://brainvisa.info>); statistical maps are projected onto a single IMAGEN participant brain mesh. The same color code as above is in use.

#### Voxel-based morphometry analysis

No between-group difference was found in TIV and WM/TIV, but GM/TIV was significantly lower, and cerebrospinal fluid/TIV higher,

in SBP (vs control) adolescents. On a regional basis, GM volume was significantly smaller in the SBP adolescents in the left anterior cingulate (ACC) (Table 2 and Figure 1).



There were no regions of larger GM volume in SBP adolescents. Voxel-based morphometry of WM images did not retrieve any significant cluster in any comparison.

#### TBSS analysis

Within the WM skeleton, SBP adolescents (vs controls) had lower FA values globally, while no between-group differences were found for MD, AD and RD global measures (Table 1).

Regionally, the SBP adolescents (vs controls) showed significantly lower FA in a large contiguous cluster (26 872 voxels, peak voxel at  $x=19$ ,  $y=-51$ ,  $z=26$  Montreal Neurologic Institute coordinates) encompassing association tracts including the cingulum bundle, bilateral superior and inferior longitudinal, inferior fronto-occipital and uncinate fasciculi; projection fibers including the corticospinal tract, and anterior thalamic radiations; and commissural fibers including the genu, body and splenium of the corpus callosum (Table 3 and Figure 1).

The SBP adolescents (vs controls) had significantly higher RD in two clusters (cluster 1: 1119 voxels, peak voxel at  $x=36$ ,  $y=-56$ ,  $z=27$ ; cluster 2: 145 voxels, peak voxel at  $x=-32$ ,  $y=-66$ ,  $z=23$ ) including posterior parts of the right cingulum, bilateral superior and inferior longitudinal fasciculi, bilateral inferior fronto-occipital fasciculi, anterior thalamic radiations and the forceps major (Table 3 and Figure 1).

There were no regions of significantly higher FA or lower RD in the SBP adolescents, and no regional between-groups difference was found in MD and AD.

In a slice-wise manner (Figure 2), the FA and RD profiles showed the distribution of the mean values slice-by-slice across the posterior-to-anterior axis of the brain for each group. On this one-dimensional summary, areas of lower FA and higher RD in SBP adolescents (vs controls) were specifically located in the posterior

regions at the coronal slice coordinate  $y=-60$ . This coronal plane includes the posterior cingulate/precuneus region.

#### DISCUSSION

This is the first study to have assessed WM microstructure and GM volumes in community adolescents with SBP. Our findings suggest widespread alterations in WM involving a number of tracts that continue to mature during adolescence. In addition, we observed a smaller left ACC GM volume in the SBP (vs control) adolescents.

Although most of SBP participants were not at familial risk for BD, it is remarkable that lower regional FA was detected in most of the tracts where decreased FA has been reported in previous studies of pediatric BD or depressed adolescent patients. The corpus callosum,<sup>14,15,48</sup> the uncinate fasciculus,<sup>49</sup> the cingulum bundle,<sup>14,15</sup> the inferior longitudinal fasciculus,<sup>15</sup> the thalamic radiations, corticospinal tracts and the superior longitudinal fasciculus<sup>14</sup> have all previously been reported to be altered in adolescents and also adults with BD.<sup>50</sup>

Several WM bundles with significant WM alterations in this study are involved in the circuitry implicated in emotional regulation. The cingulum bundle, for instance, a component of the circuitry subserving emotion, originates in various parts of the cingulate cortex, such as the rostral cingulate, and caudal cingulate, and projects rostrally to various areas implicated in mood disorders,<sup>51</sup> including the DLPFC, the ACC and orbital-frontal cortex, and caudally to the ventral temporal lobe, retrosplenial cortex and parietal cortex.<sup>52</sup> Also, WM changes were particularly marked in all parts of the corpus callosum. Most of the prefrontal fibers course through this bundle, notably the fibers originating in DLPFC and ACC, which course through the rostral part of the genu. Thus, WM alterations in those bundles might confer vulnerability to emotional dysregulation.

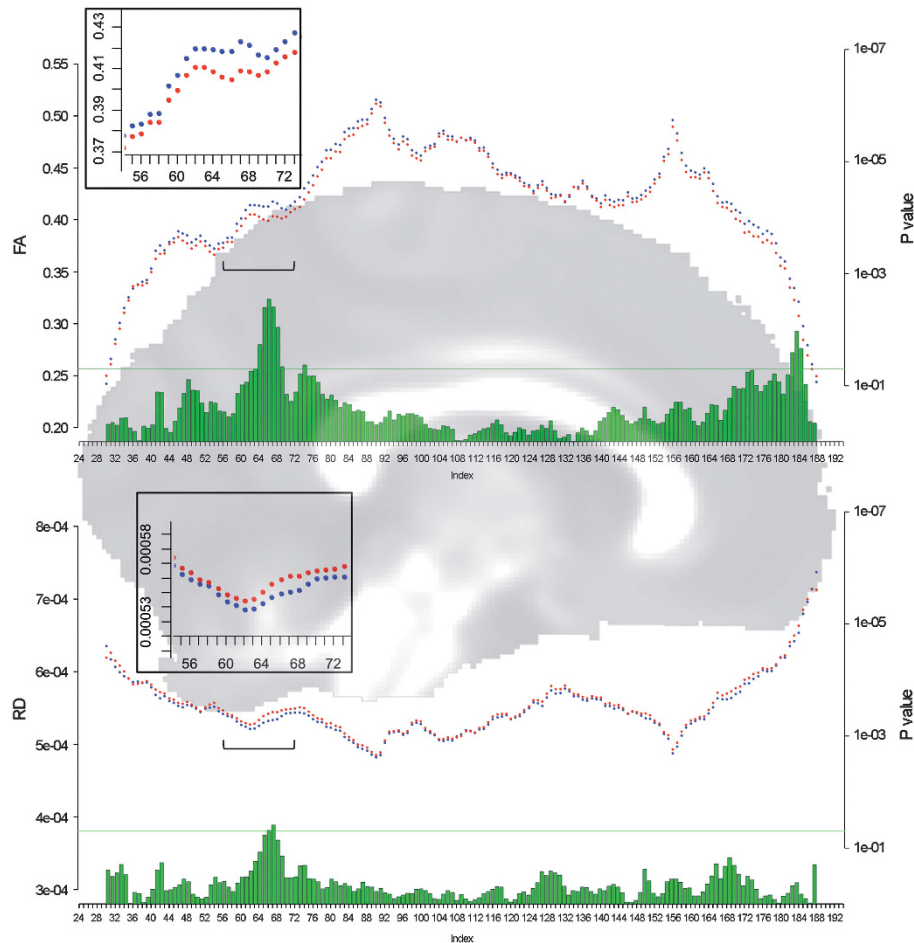
**Table 3.** Differences in FA and RD between SBP and healthy adolescents

White-matter tracts JHU white-matter tractography atlas	Lower FA in SBP		Overlapping white-matter regions of lower FA JHU ICBM-DTI-81-white-matter labels atlas	Higher RD in SBP		Overlapping white-matter regions of higher RD JHU ICBM-DTI-81-white-matter labels atlas
	Mean probabilities <sup>a</sup>	Voxels (%) <sup>b</sup>		Mean probabilities <sup>a</sup>	Voxels (%) <sup>b</sup>	
L Anterior thalamic radiation	0.43	6.81	Anterior corona radiata, anterior limb of internal capsule	0.05	1.27	NA
R Anterior thalamic radiation	0.79	7.69	Anterior corona radiata	0.22	6.88	Splenium of CC, post. thalamic radiation
L Corticospinal tract	0.84	2.96	Post. limb of internal capsule, cerebral peduncle, post. corona radiata	NA	NA	NA
R Corticospinal tract	0.62	3.83	Post. corona radiata	NA	NA	Post. corona radiata
L Cingulum	0.52	7.08		NA	NA	NA
R Cingulum	0.10	2.32		0.26	7.67	Body and splenium of CC
L Cingulum (hippocampus)	0.01	0.17		NA	NA	NA
R Cingulum (hippocampus)	0.19	2.50		0.43	12.34	Post. corona radiata, splenium of CC
L Inferior fronto-occipital fasciculus	1.62	11.09	Anterior corona radiata, retrolenticular part of internal capsule, external capsule, sagittal stratum	0.29	5.06	Post. thalamic radiation, post. corona radiata
R Inferior fronto-occipital fasciculus	2.39	15.37	Anterior corona radiata, retrolenticular part of internal capsule, external capsule, sagittal stratum	2.20	26.42	Post. corona radiata, post. thalamic radiation
L ILF	1.31	9.01	Sagittal stratum	0.53	9.10	L Post. corona radiata, post. thalamic radiation
R ILF	1.37	12.12	Sagittal stratum	1.55	21.84	R Post thalamic radiation, post corona radiata
L SLF	2.08	14.70		0.24	6.17	L Post corona radiata
R SLF	1.04	9.08		5.46	44.15	Post. thalamic radiation, SLF
L SLF (temporal)	1.04	9.14		0.05	1.66	L SLF (temporal)
R SLF (temporal)	0.35	2.97		2.54	15.74	R SLF (temporal)
L Uncinate fasciculus	0.48	4.31		NA	NA	NA
R Uncinate fasciculus	0.14	2.15		NA	NA	NA
Forceps minor	5.40	13.68	Anterior corona radiata, genu of corpus callosum	NA	NA	NA
Forceps major	0.84	7.4	Splenium of corpus callosum	0.74	14.72	Post. corona radiata, post. thalamic radiation, splenium of CC

Abbreviations: CC, corpus callosum; FA, fractional anisotropy; ILF, inferior longitudinal fasciculus; L, left; NA, not applicable; Post., posterior; R, right; RD, radial diffusivity; SBP, subthreshold bipolar subjects; SLF, superior longitudinal fasciculus. Statistical significance was set at  $P < 0.05$ , FWE (family wise error) corrected.

<sup>a</sup>Mean probabilities of the considered tract within the mask of results (outputs from 'atlasquery' of FSL).

<sup>b</sup>Percentage of voxels of the considered tract within the mask of results.



**Figure 2.** Plots of mean fractional anisotropy (FA) (top) and mean radial diffusivity (RD) (bottom) along the posterior to anterior y axis (mm) of the white-matter skeleton. Red dots indicate values in subthreshold bipolar adolescents; blue dots indicate values in the controls; green bars indicate  $P$ -values; and green horizontal line the  $P < 0.05$  statistical threshold. Boxes indicate zoomed plots between slices 56 and 72.

Among the other bundles with WM integrity alterations in the SBP group, the uncinate fasciculus is worth noting as it links the anterior temporal lobe and amygdala with the medial and orbital prefrontal cortices, and as such appears to be implicated in the regulation of behavior expression and emotional responses subserved by those structures.<sup>53</sup>

Adolescence is a critical period for WM and GM maturation, involving widespread reductions in cortical GM volume, increases in WM volume and FA and decreased RD and AD.<sup>54–58</sup> WM maturation involves both myelination and axonal caliber increases, but the maturation mechanisms seem region-dependent and are still debated.<sup>56,59,60</sup> Considerable variation has been reported in age-related FA changes across tracts, suggesting a hierarchical pattern of maturation in which some connections develop more slowly than others.<sup>56</sup> It has been shown that WM development takes place along a posterorostral gradient, and that WM in posterior regions tends to develop earlier and faster.<sup>61</sup> Our results indicate that WM integrity alterations in the SBP group were more distinct in the posterior cingulate regions, with lower FA and higher RD in the posterior regions, as denoted by the slice-wise analysis of the mean FA and RD values in each coronal slice along the posterorostral axis. RD decrease has been reported in postpubertal stage;<sup>62</sup> therefore, pubertal status of the SBP group cannot account for the higher RD, as the SBP adolescents had higher pubertal status as compared with controls. Thus, the FA and RD changes in this study point out possibly reduced or delayed WM maturation, in

the SBP adolescents, who might be lagging ‘behind’ the controls in a number of WM bundles, notably in regions that develop faster than others in early adolescence.

It is noteworthy that the posterior part of the cingulate bundle is adjacent to the PCC/precuneus region encompassing Brodmann areas 23/31, which also showed a trend for lower *gray matter* volume in the SBP adolescents. The posterior cingulate/precuneus has been identified as a prominent ‘hub’, central to resting connectivity networks for integration of neural processing; the dysfunction of such a region, which might develop with GM changes, has been hypothesized to contribute to psychiatric diseases.<sup>63</sup>

These WM findings were also concomitant to smaller regional GM volumes in SBP subjects in the ‘affective division’ of the ACC,<sup>64</sup> and to a lesser extent in the medial prefrontal cortex, both regions where the cingulum bundle originates and projects. The ACC affective division is involved in assessing the salience of emotional and motivational information and the regulation of emotional responses, and is part of a medial prefrontal network involved in self-referential functions where GM decreases have been reported in early-onset recurrent major depression or BD.<sup>51</sup> Of note, the age of peak cortical thickness in the cingulate has been found around 14 years,<sup>65</sup> which is precisely the mean age of this sample.

Smaller GM volume in those prefrontal regions, associated with delayed WM maturation in projecting bundles, might contribute to inadequate modulation of subcortical structures, and lead to mood dysregulation, which could underlie vulnerability to BD. Indeed, a recent model postulates that reduced prefrontal

modulation of subcortical and medial temporal structures within the anterior limbic network, associated with early WM abnormalities, contributes to further developmental abnormalities involving prefrontal connections with the amygdala, a structure supposed to be at the core of emotional dysregulation in BD.<sup>66,67</sup> Lower amygdala volume is the most replicated neuroanatomical finding in adolescents with BD.<sup>68</sup> However, in line with our findings, no change in amygdala volume has been reported in adolescents at onset of BD,<sup>69,70</sup> nor in youth at familial risk for BD.<sup>71,72</sup>

Thus, these findings in the SBP adolescents, showing both WM microstructure alterations in the frontal-limbic pathways and lower ACC/medial prefrontal GM volumes, support an altered interplay between WM and GM maturation in the GM regions and WM tracts involved in mood regulation, which might lead to later amygdala development abnormalities.

### Limitations

The main limitation is the lack of known outcome of the participants. Indeed, the SBP adolescents had no prior psychiatry history, nor were they at more 'familial risk' of affective disorders than the controls. Thus, the SBP adolescents may have expressed extreme personality features in the range of normal mood instability. However, the inclusion symptoms were core symptoms of mania whose rates have been found to be high (82% for expansive mood and pressure of speech; 90% for unstable mood, 57% for sleep decrease) in adolescent SBP, and have proved to have a significant pathological meaning as regards outcomes.<sup>30</sup> Furthermore, the SBP adolescents had significantly higher SDQ emotional and behavioral difficulties scores, which has been related with overall social impairment.<sup>47</sup> Yet, given the outcomes of subjects with SBP,<sup>6,9</sup> it is difficult to interpret the meaning of the findings with regard to a specific disorder, as those early WM and GM alterations might reflect vulnerability to BD or to anxiety or depression as well. In addition, the risk of developing depression in adolescence has been related to pubertal status,<sup>73</sup> which is consistent with the higher pubertal status in the present SBP group, although the groups were matched by sex and age.

The pathophysiological significance of altered directional diffusivities in relation to WM pathology is an ongoing area of research. DTI parameters could reflect several facets of WM, as axonal size, density, coherence and membrane structure, or lipid, protein and macromolecule content, or water compartmentalization. Previous studies have reported that lower FA might indicate decreased fiber organization and coherence, notably when associated with increased RD,<sup>74</sup> or lack of myelin,<sup>75</sup> and/or changes in other structural components of the axon and WM microenvironment. The absence of axial diffusivity change might reflect preserved axonal integrity, while radial diffusivity might inform on myelin sheaths.<sup>75</sup> Thus, reduced FA with increased RD, and no axial diffusivity changes, as in the present SBP group, could indicate altered myelination without axonal loss. However, the histology and molecular changes in oligodendrocytes and myelin microenvironment reflected by DTI alterations cannot be tested in humans by noninvasive techniques.

In summary, our results suggest that SBP in adolescents is associated with structural connectivity alterations likely to affect the development of WM bundles and connected GM areas involved in emotion regulation.

### CONFLICT OF INTEREST

RG is the owner of Youthinmind, which provides no-cost and low-cost software and websites related to the Development and Well-Being Assessment and the Strengths and Difficulties Questionnaire. TR receives compensation as a consultant for Cambridge Cognition. The remaining authors declare no conflict of interest.

### ACKNOWLEDGEMENTS

This study was supported by the European Community's Sixth Framework Program (LSHM-CT-2007-037286), by an APHP/INSERM interface grant from the Assistance Publique-Hôpitaux de Paris and the French Institute for Health and Medical Research, and by a collaborative project grant-2010 from Paris-Descartes University. This manuscript reflects only the authors' views and the community is not liable for any use that may be made of the information contained therein.

### REFERENCES

- 1 Tijssen MJ, van Os J, Wittchen HU, Lieb R, Beesdo K, Mengelers R et al. Evidence that bipolar disorder is the poor outcome fraction of a common developmental phenotype: an 8-year cohort study in young people. *Psychol Med* 2010; **40**: 289–299.
- 2 Casey BJ, Jones RM, Levita L, Libby V, Pattwell SS, Ruberry EJ et al. The storm and stress of adolescence: insights from human imaging and mouse genetics. *Dev Psychobiol* 2010; **52**: 225–235.
- 3 Lewinsohn PM, Klein DN, Seeley JR. Bipolar disorder during adolescence and young adulthood in a community sample. *Bipolar Disord* 2000; **2**: 281–293.
- 4 Nusslock R, Frank E. Subthreshold bipolarity: diagnostic issues and challenges. *Bipolar Disord* 2011; **13**: 587–603.
- 5 Lewinsohn PM, Klein DN, Seeley JR. Bipolar disorders in a community sample of older adolescents: prevalence, phenomenology, comorbidity, and course. *J Am Acad Child Adolesc Psychiatry* 1995; **34**: 454–463.
- 6 Birmaher B, Axelson D, Goldstein B, Strober M, Gill MK, Hunt J et al. Four-year longitudinal course of children and adolescents with bipolar spectrum disorders: the Course and Outcome of Bipolar Youth (COBY) study. *Am J Psychiatry* 2009; **166**: 795–804.
- 7 Axelson DA, Birmaher B, Strober MA, Goldstein BI, Ha W, Gill MK et al. Course of subthreshold bipolar disorder in youth: diagnostic progression from bipolar disorder not otherwise specified. *J Am Acad Child Adolesc Psychiatry* 2011; **50**: 1001–1016.
- 8 Tijssen MJ, van Os J, Wittchen HU, Lieb R, Beesdo K, Mengelers R et al. Prediction of transition from common adolescent bipolar experiences to bipolar disorder: 10-year study. *Br J Psychiatry* 2010; **196**: 102–108.
- 9 Shankman SA, Lewinsohn PM, Klein DN, Small JW, Seeley JR, Altman SE. Subthreshold conditions as precursors for full syndrome disorders: a 15-year longitudinal study of multiple diagnostic classes. *J Child Psychol Psychiatry* 2009; **50**: 1485–1494.
- 10 Barnea-Goraly N, Chang KD, Karchemskiy A, Howe ME, Reiss AL. Limbic and corpus callosum aberrations in adolescents with bipolar disorder: a tract-based spatial statistics analysis. *Biol Psychiatry* 2009; **66**: 238–244.
- 11 Adler CM, Adams J, DelBello MP, Holland SK, Schmithorst V, Levine A et al. Evidence of white matter pathology in bipolar disorder adolescents experiencing their first episode of mania: a diffusion tensor imaging study. *Am J Psychiatry* 2006; **163**: 322–324.
- 12 Chen HH, Nicoletti MA, Hatch JP, Sassi RB, Axelson D, Brambilla P et al. Abnormal left superior temporal gyrus volumes in children and adolescents with bipolar disorder: a magnetic resonance imaging study. *Neurosci Lett* 2004; **363**: 65–68.
- 13 Versace A, Ladouceur CD, Romero S, Birmaher B, Axelson DA, Kupfer DJ et al. Altered development of white matter in youth at high familial risk for bipolar disorder: a diffusion tensor imaging study. *J Am Acad Child Adolesc Psychiatry* 2010; **49**: 1249–1259.
- 14 Huang H, Fan X, Williamson DE, Rao U. White matter changes in healthy adolescents at familial risk for unipolar depression: a diffusion tensor imaging study. *Neuropsychopharmacology* 2011; **36**: 684–691.
- 15 Frazier JA, Breeze JL, Papadimitriou G, Kennedy DN, Hodge SM, Moore CM et al. White matter abnormalities in children with and at risk for bipolar disorder. *Bipolar Disord* 2007; **9**: 799–809.
- 16 Chen MC, Hamilton JP, Gotlib IH. Decreased hippocampal volume in healthy girls at risk of depression. *Arch Gen Psychiatry* 2010; **67**: 270–276.
- 17 DelBello MP, Zimmerman ME, Mills NP, Getz GE, Strakowski SM. Magnetic resonance imaging analysis of amygdala and other subcortical brain regions in adolescents with bipolar disorder. *Bipolar Disord* 2004; **6**: 43–52.
- 18 Wilke M, Kowatch RA, DelBello MP, Mills NP, Holland SK. Voxel-based morphometry in adolescents with bipolar disorder: first results. *Psychiatry Res* 2004; **131**: 57–69.
- 19 MacMaster FP, Kusumakar V. Hippocampal volume in early onset depression. *BMC Med* 2004; **2**: 2.
- 20 Kaur S, Sassi RB, Axelson D, Nicoletti M, Brambilla P, Monkul ES et al. Cingulate cortex anatomical abnormalities in children and adolescents with bipolar disorder. *Am J Psychiatry* 2005; **162**: 1637–1643.



- 21 Frazier JA, Chiu S, Breeze JL, Makris N, Lange N, Kennedy DN *et al*. Structural brain magnetic resonance imaging of limbic and thalamic volumes in pediatric bipolar disorder. *Am J Psychiatry* 2005; **162**: 1256–1265.
- 22 Dickstein DP, Milham MP, Nugent AC, Drevets WC, Charney DS, Pine DS *et al*. Frontotemporal alterations in pediatric bipolar disorder: results of a voxel-based morphometry study. *Arch Gen Psychiatry* 2005; **62**: 734–741.
- 23 Blumberg HP, Krystal JH, Bansal R, Martin A, Dziura J, Durkin K *et al*. Age, rapid-cycling, and pharmacotherapy effects on ventral prefrontal cortex in bipolar disorder: a cross-sectional study. *Biol Psychiatry* 2006; **59**: 611–618.
- 24 Gogtay N, Ordonez A, Herman DH, Hayashi KM, Greenstein D, Vaituzis C *et al*. Dynamic mapping of cortical development before and after the onset of pediatric bipolar illness. *J Child Psychol Psychiatry* 2007; **48**: 852–862.
- 25 Schumann G, Loth E, Banaschewski T, Barbot A, Barker G, Büchel C *et al*. The IMAGEN study: reinforcement-related behaviour in normal brain function and psychopathology. *Mol Psychiatry* 2010; **15**: 1128–1139.
- 26 Goodman R, Ford T, Richards H, Gatward R, Meltzer H. The Development and Well-Being Assessment: description and initial validation of an integrated assessment of child and adolescent psychopathology. *J Child Psychol Psychiatry* 2000; **41**: 645–655.
- 27 Kraepelin E. *Leçons cliniques sur la démence précoce et la psychose maniaco-dépressive*. Privat, Toulouse, France, 1970.
- 28 Young MA, Abrams R, Taylor MA, Meltzer HY. Establishing diagnostic criteria for mania. *J Nerv Ment Dis* 1983; **171**: 676–682.
- 29 Axelson D, Birmaher B, Strober M, Gill MK, Valeri S, Chiappetta L *et al*. Phenomenology of children and adolescents with bipolar spectrum disorders. *Arch Gen Psychiatry* 2006; **63**: 1139–1148.
- 30 Clayton PJ, Pitts Jr FN, Winokur G. Affective disorder. IV. Mania. *Compr Psychiatry* 1965; **6**: 313–322.
- 31 Geller B, Tillman R. Prepubertal and early adolescent bipolar I disorder: review of diagnostic validation by Robins and Guze criteria. *J Clin Psychiatry* 2005; **66**(Suppl 7): 21–28.
- 32 Mebane Jr WR, Sekhon JS. Genetic optimization using derivatives: the rgenoud package for R. *J Stat Softw* 2011; **42**: 1–26.
- 33 Saunders JB, Aasland OG, Babor TF, de la Fuente JR, Grant M. Development of the Alcohol Use Disorders Identification Test (AUDIT): WHO Collaborative Project on Early Detection of Persons with Harmful Alcohol Consumption—II. *Addiction* 1993; **88**: 791–804.
- 34 Hibell B, Andersson B, Bkarnason T, Kokkevi A, Morgan M, Narusk A. *The 1995 ESPAD Report: Alcohol and other Drug use Among Students in 26 European Countries*. Swedish Council for Information on Alcohol and Other Drugs: Stockholm, Sweden, 1997.
- 35 Goodman R. The Strengths and Difficulties Questionnaire: a research note. *J Child Psychol Psychiatry* 1997; **38**: 581–586.
- 36 Petersen A, Crockett L, Richards M, Boxer A. A self-report measure of pubertal status: reliability, validity, and initial norms. *J Youth Adolesc* 1988; **17**: 117–133.
- 37 Ashburner J, Friston KJ. Unified segmentation. *NeuroImage* 2005; **26**: 839–851.
- 38 Smith SM. Fast robust automated brain extraction. *Hum Brain Mapp* 2002; **17**: 143–155.
- 39 Smith SM, Jenkinson M, Johansen-Berg H, Rueckert D, Nichols TE, Mackay CE *et al*. Tract-based spatial statistics: voxelwise analysis of multi-subject diffusion data. *NeuroImage* 2006; **31**: 1487–1505.
- 40 Andersson JLR, Jenkinson M, Smith S. *Non-linear optimisation*. FMRIB technical report TR07JA1; available at: [www.fmrib.ox.ac.uk/analysis/techrep](http://www.fmrib.ox.ac.uk/analysis/techrep), 2007.
- 41 Andersson JLR, Jenkinson M, Smith S. *Non-linear registration, aka spatial normalisation*. FMRIB technical report TR07JA2; available at: [www.fmrib.ox.ac.uk/analysis/techrep](http://www.fmrib.ox.ac.uk/analysis/techrep), 2007.
- 42 Rueckert D, Sonoda LI, Hayes C, Hill DL, Leach MO, Hawkes DJ. Nonrigid registration using free-form deformations: application to breast MR images. *IEEE Trans Med Imag* 1999; **18**: 712–721.
- 43 Nugent AC, Milham MP, Bain EE, Mah L, Cannon DM, Marrett S *et al*. Cortical abnormalities in bipolar disorder investigated with MRI and voxel-based morphometry. *NeuroImage* 2006; **30**: 485–497.
- 44 Maldjian JA, Laurienti PJ, Kraft RA, Burdette JH. An automated method for neuroanatomic and cytoarchitectonic atlas-based interrogation of fMRI data sets. *NeuroImage* 2003; **19**: 1233–1239.
- 45 Mori S, Oishi K, Jiang H, Jiang L, Li X, Akhter K *et al*. Stereotaxic white matter atlas based on diffusion tensor imaging in an ICBM template. *NeuroImage* 2008; **40**: 570–582.
- 46 Wakana S, Caprihan A, Panzenboeck MM, Fallon JH, Perry M, Gollub RL *et al*. Reproducibility of quantitative tractography methods applied to cerebral white matter. *NeuroImage* 2007; **36**: 630–644.
- 47 Stringaris A, Stahl D, Santosh P, Goodman R. Dimensions and latent classes of episodic mania-like symptoms in youth: an empirical enquiry. *J Abnorm Child Psychol* 2011; **39**: 925–937.
- 48 Lopez-Larson M, Breeze JL, Kennedy DN, Hodge SM, Tang L, Moore C *et al*. Age-related changes in the corpus callosum in early-onset bipolar disorder assessed using volumetric and cross-sectional measurements. *Brain Imag Behav* 2010; **4**: 220–231.
- 49 Cullen KR, Klimes-Dougan B, Muetzel R, Mueller BA, Camchong J, Hourii A *et al*. Altered white matter microstructure in adolescents with major depression: a preliminary study. *J Am Acad Child Adolesc Psychiatry* 2010; **49**: 173–183.e1.
- 50 Mahon K, Burdick KE, Szeszko PR. A role for white matter abnormalities in the pathophysiology of bipolar disorder. *Neurosci Biobehav Rev* 2010; **34**: 533–554.
- 51 Drevets WC, Price JL, Furey ML. Brain structural and functional abnormalities in mood disorders: implications for neurocircuitry models of depression. *Brain Struct Funct* 2008; **213**: 93–118.
- 52 Schmahmann JD, Pandya DN. *Fiber Pathways of the Brain*. Oxford University Press: New York, NY, USA, 2006.
- 53 Hooker CJ, Knight RT. The role of the lateral orbitofrontal cortex in the inhibitory control of emotion. In Zald DH, Rauch SL (eds). *The Orbitofrontal Cortex*. Oxford University Press: Oxford, UK, 2006, pp 307–324.
- 54 Paus T, Zijdenbos A, Worsley K, Collins DL, Blumenthal J, Giedd JN *et al*. Structural maturation of neural pathways in children and adolescents: *in vivo* study. *Science* 1999; **283**: 1908–1911.
- 55 Gogtay N, Giedd JN, Lusk L, Hayashi KM, Greenstein D, Vaituzis AC *et al*. Dynamic mapping of human cortical development during childhood through early adulthood. *Proc Natl Acad Sci USA* 2004; **101**: 8174–8179.
- 56 Lebel C, Walker L, Leemans A, Phillips L, Beaulieu C. Microstructural maturation of the human brain from childhood to adulthood. *NeuroImage* 2008; **40**: 1044–1055.
- 57 Giorgio A, Watkins KE, Chadwick M, James S, Winmill L, Douaud G *et al*. Longitudinal changes in grey and white matter during adolescence. *NeuroImage* 2010; **49**: 94–103.
- 58 Faria AV, Zhang J, Oishi K, Li X, Jiang H, Akhter K *et al*. Atlas-based analysis of neurodevelopment from infancy to adulthood using diffusion tensor imaging and applications for automated abnormality detection. *NeuroImage* 2010; **52**: 415–428.
- 59 Paus T, Keshavan M, Giedd JN. Why do many psychiatric disorders emerge during adolescence? *Nat Rev Neurosci* 2008; **9**: 947–957.
- 60 Perrin JS, Hervé PY, Leonard G, Perron M, Pike GB, Pitiot A *et al*. Growth of white matter in the adolescent brain: role of testosterone and androgen receptor. *J Neurosci* 2008; **28**: 9519–9524.
- 61 Colby JB, Van Horn JD, Sowell ER. Quantitative *in vivo* evidence for broad regional gradients in the timing of white matter maturation during adolescence. *NeuroImage* 2011; **54**: 25–31.
- 62 Asato MR, Terwilliger R, Woo J, Luna B. White matter development in adolescence: a DTI study. *Cereb Cortex* 2010; **20**: 2122–2131.
- 63 Tomasi D, Volkow ND. Functional connectivity density mapping. *Proc Natl Acad Sci USA* 2010; **107**: 9885–9890.
- 64 Bush G, Luu P, Posner MI. Cognitive and emotional influences in anterior cingulate cortex. *Trends Cogn Sci* 2000; **4**: 215–222.
- 65 Sullivan EV, Pfefferbaum A, Rohlfing T, Baker FC, Padilla ML, Colrain IM. Developmental change in regional brain structure over 7 months in early adolescence: Comparison of approaches for longitudinal atlas-based parcellation. *NeuroImage* 2011; **57**: 214–224.
- 66 Strakowski SM. Integration and consolidation. A neurophysiological model of bipolar disorder. In Strakowski SM (ed) *The Bipolar Brain. Integrating Neuroimaging and Genetics*. Oxford University Press: New York, NY, USA, 2012, pp 253–273.
- 67 Strakowski SM, Adler CM, Almeida J, Altshuler LL, Blumberg HP, Chang KD *et al*. The functional neuroanatomy of bipolar disorder: a consensus model. *Bipolar Disord* 2012; **14**: 313–325.
- 68 Singh MK, DelBello MP, Chang KD. Neuroimaging studies of bipolar disorder in youth. In Strakowski SM (ed) *The Bipolar Brain. Integrating Neuroimaging and Genetics*. Oxford University Press: New York, NY, USA, 2012, pp 103–123.
- 69 Bitter SM, Mills NP, Adler CM, Strakowski SM, DelBello MP. Progression of amygdala volumetric abnormalities in adolescents after their first manic episode. *J Am Acad Child Adolesc Psychiatry* 2011; **50**: 1017–1026.
- 70 Singh MK, Chang KD, Chen MC, Kelley RG, Garrett A, Mitsunaga MM *et al*. Volumetric reductions in the subgenual anterior cingulate cortex in adolescents with bipolar I disorder. *Bipolar Disord* 2012; **14**: 585–596.
- 71 Ladouceur CD, Almeida JR, Birmaher B, Axelson DA, Nau S, Kalas C *et al*. Subcortical gray matter volume abnormalities in healthy bipolar offspring: potential neuroanatomical risk marker for bipolar disorder? *J Am Acad Child Adolesc Psychiatry* 2008; **47**: 532–539.



- 72 Karchemskiy A, Garrett A, Howe M, Adleman N, Simeonova DI, Alegria D *et al*. Amygdalar, hippocampal, and thalamic volumes in youth at high risk for development of bipolar disorder. *Psychiatry Res* 2011; **194**: 319–325.
- 73 Angold A, Costello EJ, Worthman CM. Puberty and depression: the roles of age, pubertal status and pubertal timing. *Psychol Med* 1998; **28**: 51–61.
- 74 Choe AS, Stepniewska I, Colvin DC, Ding Z, Anderson AW. Validation of diffusion tensor MRI in the central nervous system using light microscopy: quantitative comparison of fiber properties. *NMR Biomed* 2012; **25**: 900–908.

## APPENDIX

### IMAGEN consortium (other participants):

Reed L, Williams S, Lourdasamy A, Costafreda S, Cattrell A, Nymberg C, Topper L, Smith L, Havatzias S, Stueber K, Mallik C, Clarke TK, Stacey D, Peng Wong C, Werts H, Williams S, Andrew C, Desrivieres S, Zewdie S, Häke I, Ivanov N, Klär A, Reuter J, Palafox C, Hohmann C, Schilling C, Lüdemann K, Romanowski A, Ströhle A, Wolff E, Rapp M, Brühl R, Ihlenfeld A, Walaszek B, Schubert F, Connolly C, Jones J, Lalor E, McCabe E, Ní Shiothcháin A, Whelan R, Spanagel R, Leonardi-Essmann F, Sommer W, Vollstaedt-Klein S, Nees F, Steiner S, Buehler M, Stolzenburg E, Schmal C, Schirmbeck

- 75 Song SK, Sun SW, Ramsbottom MJ, Chang C, Russell J, Cross AH. Dysmyelination revealed through MRI as increased radial (but unchanged axial) diffusion of water. *NeuroImage* 2002; **17**: 1429–1436.



This work is licensed under a Creative Commons Attribution-NonCommercial-ShareAlike 3.0 Unported License. To view a copy of this license, visit <http://creativecommons.org/licenses/by-nc-sa/3.0/>

F, Gowland P, Heym N, Newman C, Huebner T, Ripke S, Mennigen E, Muller K, Ziesch V, Büchel C, Bromberg U, Lueken L, Yacubian J, Finsterbusch J, Bordas N, de Bournonville S, Bricaud Z, Gollier Briand F, Massicotte J, Poline JB, Vulser H, Schwartz Y, Lalanne C, Frouin V, Thyreau B, Dalley J, Mar A, Subramaniam N, Theobald D, Richmond N, de Rover M, Molander A, Jordan E, Robinson E, Hipolata L, Moreno M, Arroyo M, Stephens D, Ripley T, Crombag H, Pena Y, Lathrop M, Zelenika D, Heath S, Lanzerath D, Heinrichs B, Spranger T, Fuchs B, Speiser C, Resch F, Haffner J, Parzer P, Brunner R, Klaassen A, Klaassen I, Constant P, Mignon X, Thomsen T, Zysset S, Vestboe A, Ireland J, Rogers J.