



MATTERS SELECT 25/30

Unique characterization of Langerhans cells in the spleen of the African catfish (*Clarias gariepinus*).

Discipline

Biological

Keywords

Cat Fish

Langerhans-Like Cells

Spleen

Ultrastructure

Cd1a

Observation Type

Standalone

Nature

Orphan Data

Submitted

Jan 20th, 2017

Published

Jul 21st, 2017

Doaa M Zaghloul, Amira E Derbalah, Catrin S Rutland

Jul 21st, 2017 · Score: 25/30 · 10.19185/matters.201703000005  [Article](#)[Authors](#)[Reviews](#)[Info](#)

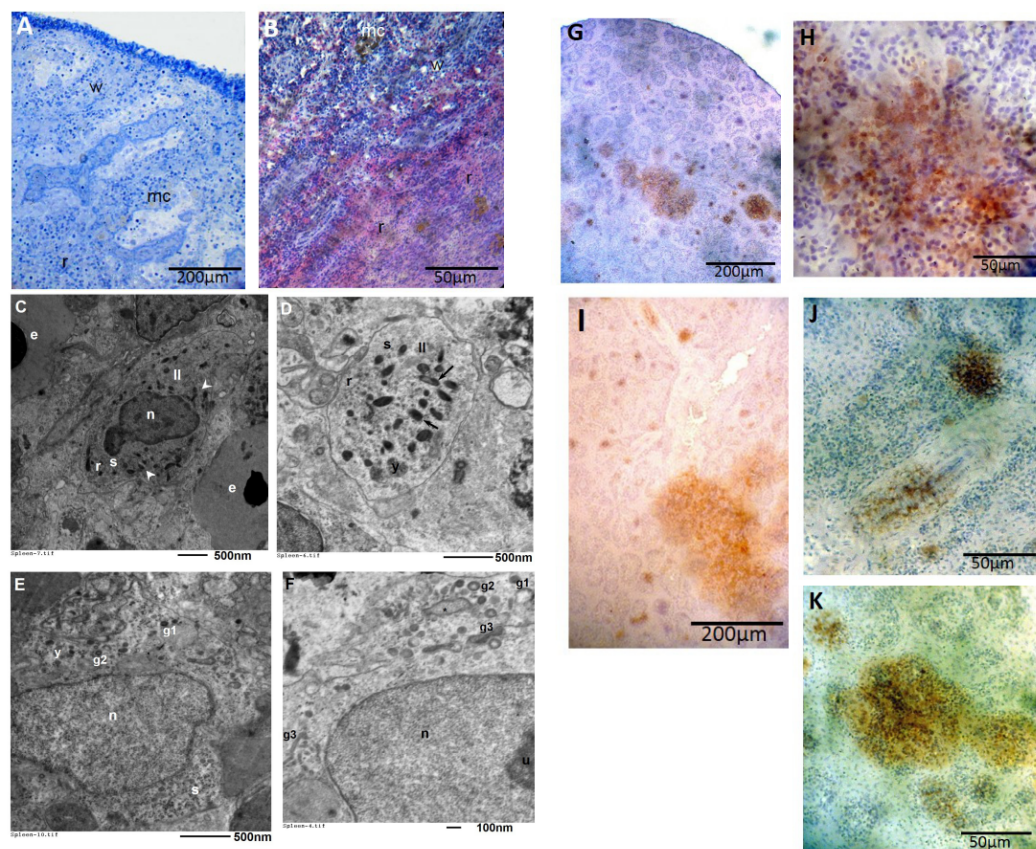
Abstract

The African catfish (*Clarias gariepinus*) has increasingly become an economically important food source especially in Africa, Asia and Europe, with exports extending to countries throughout the world. In the last 25 years, aquaculture of this species has been particularly effective with large increases in production and this is in part due to the catfish being highly resistant to disease. In order to further understand the immune system of the catfish, the spleen was investigated using a number of staining, immunohistochemical, light and transmission electron microscope techniques in order to verify the histological features of this organ. The gross histological features of the spleen confirmed the presence of a capsule containing numerous collagen fibers surrounded the spleen of the African catfish. Melanomacrophage centers, lymphocytes and surrounding arterial vessels were the main components of the white pulp whilst the red pulp contained sinusoids, capillaries and splenic cords of erythrocytes, macrophages and lymphocytes. Transmission electron microscopy identified Langerhans-like cells which were irregular to ovoid in shape with an electron lucent cytoplasm. The cells were characterized by the presence of numerous Birbeck-like granules, varying in shape from oval, round, rod to racket shaped granules. In total, three types of Birbeck-like granules were identified. The first type had heterogenic content, the second type were cored granules and the third type were racket shaped granules. Some of the racket shaped granules were enlarged and contained granular content. The Langerhans-like cells were further identified and characterised by showing a positive reaction with antibodies to S100 and



CD1a. The existence of Langerhans-like cells within the spleen helps to identify the components of the immune system within the African catfish.

Figure



a

A) Toludin blue light photomicrograph of the African catfish (*Claris gariepinus*) spleen showing white bulp (w), red pulp (r) and melanomacrophage center (mc), 100X Mag, scale bar represents 200 μ m.

B) Light photomicrograph of the haematoxylin and eosin stained capsule showing white bulp (w), red pulp (r) and melanomacrophage center (mc), 400X Mag scale bar represents 50 μ m.

C) Transmission electron micrograph of catfish spleen showing Langerhans-like cells (ll), Birbeck-like granules (arrow head), rough endoplasmic reticulum (r), ribosomes (s), nucleus (n) and erythrocytes (e) and lysosomes (y). 3000X Mag, scale bar represents 500 nm.

D) Transmission electron micrograph of catfish spleen showing Langerhans-like cells (ll), Birbeck-like granules (arrow head), rough endoplasmic reticulum (r), ribosomes (s) and lysosomes (y). 5000X Mag, scale bar represents 500 nm.

E) Transmission electron micrograph of Langerhans-like cell denoting three types of Birbeck-like granules- heterogenic granules (g1), cored granules (g2), racket shaped granules (g3), nucleus (n), ribosomes (s), rough endoplasmic reticulum (r) and lysosomes (y). 5000X Mag, scale bar represents 500 nm.

F) Transmission electron micrograph of Langerhans-like cell denoting three types of Birbeck-like granules- heterogenic granules (g1), cored granules (g2), racket shaped granules (g3), nucleus (n) and nucleolus (U), note enlarged racket shape granules (*). 7500X Mag, scale bar represents 100 nm.

G) Light photomicrograph of the catfish spleen depicting locations of S100 DAB immunostaining, indicative of Langerhans-like cells distributed throughout the spleen including in the red pulp and around blood vessels. 100X Mag, scale bar represents 200 μ m.

H) Light photomicrograph of the catfish spleen depicting locations of S100 DAB immunostaining, indicative of Langerhans-like cells distributed throughout the spleen including in the red pulp and around blood vessels. 400X Mag, scale bar represents 50 μ m.

I) Light photomicrograph of the catfish spleen depicting locations of CD1a DAB immunostaining, indicative of Langerhans-like cells distributed throughout the spleen including in the red pulp and around blood vessels. 100X Mag, scale bar represents 200 μ m.

J) Light photomicrograph of the catfish spleen depicting locations of CD1a DAB immunostaining, indicative of Langerhans-like cells distributed throughout the spleen including in the red pulp and around blood vessels. 400X Mag, scale bar represents 50 μ m.

K) Light photomicrograph of the catfish spleen depicting locations of CD1a DAB immunostaining, indicative of Langerhans-like cells distributed throughout the spleen including in the red pulp and around blood vessels. 400X Mag, scale bar represents 50 μ m.

Introduction

The African catfish is an important freshwater fish in terms of commercial gains with global capture and aquaculture production standing at 55,417 and 237,124 tonnes respectively in 2014, a rise from 15,000 tonnes in 1950 and 5,013 tonnes in 1992^[1]. There has been considerable concern in relation food security and availability with the increasing demands of the population, in particular the need for animal

protein, to ensure appropriate health and growth of global populations^[2]. In recent years, there has been increasing interest in farming catfish as a source of nutrition as they withstand difficult environmental conditions, have a relatively high growth rate, and the consumer holds it as an attractive food source^[3]. Despite the name, the African catfish is now also present across Asia and Europe and is exported to countries throughout the world^[1]. Catfish are highly resistant to diseases and the fish have shown high resilience to being raised in hot and dry areas, making them economically viable and sustainable^[4].

The spleen and kidney in teleost fish are the primary haemopoietic organs as the modularly cavity is not present in their bones^[5]. The spleen is also responsible for antigen trapping as fish have no lymph nodes^[6]. Dendritic cells link the innate and adaptive immune responses by directing host cells upon recognising antigens during the early stages of invasion or insult^{[7][8][9]}. Langerhans cells are a type of dendritic cell which identified as containing unique Birbeck granules^{[10][11]}. More recently vascular dendritic cells from atherosclerotic patients were also characterized as containing Birbeck granule-like structures in addition to dense granules^[12]. In salmonid fish, cells similar to Langerhans cells have been detected and their classification was based upon the presence of Birbeck-like granules^[13]. Although Langerhans cells were originally thought to be specific to epidermal tissues, they have also been found in healthy spleen and kidney and diseased gills in salmonids^{[13][14]}. CD1a and S100 are both present in Langerhans cells in the skin, whereas dendritic cells in the superficial lymph nodes are negative for CD1a and positive for S100 whilst CD1a negative cells, S100 cells are characterised as interdigitating cells^{[15][16]}. Follicular dendritic cells also express S100, it is of interest that their origin and roles are different to other hematopoietic dendritic cells^[17]. The specific immunophenotypic profile is helpful distinguishing Langerhans cells, in addition the detection of Birbeck granules, seen in both pathological and resting Langerhans cell is a prominent feature^[18].

Objective

The objective of this study was to further understand the immune system of the fish by characterising the cells and structure observed in the catfish spleen. Histological and immunohistochemical evaluations were further undertaken on the splenic Langerhans cells in order to confirm their presence in the tissue.

Results & Discussion

The spleen of the African catfish (*Clarias gariepinus*) was surrounded by connective tissue capsule consisted mainly of collagen fibers. The white pulp was mainly composed of the melanomacrophage center, lymphocytes and surrounding arterial vessels. The red pulp contained sinusoids, capillaries and splenic cords of erythrocytes, in addition to macrophages and lymphocytes (Fig. A+B) and ellipsoid capillary branches.

Using transmission electron microscope, Langerhans-like cells were observed in between the cells of spleen of catfish, they were irregular to ovoid in shape (Fig. C). Their nuclei were ovoid in shape and sometimes lobulated. No desmosomes could be seen between Langerhans-like cells and neighbouring cells (Fig. C). The Langerhans-like cell cytoplasm was electron lucent and characterized by the presence of numerous Birbeck-like granules in several shapes, varying from oval to round, rod to racket shaped granules (Fig. D). In addition to identifying the rough endoplasmic reticulum, free ribosomes and lysosomes within the Langerhans-like cells (Fig. E), three types of Birbeck-like granules were identified. The first Birbeck-like granule type had heterogenic content, the second type identified were cored granules and the third type were racket shaped granules, some of these latter racket shaped granules were enlarged with granular content (Fig. F).

Immunohistochemical staining showed that both the S100 (Fig. G+H) and CD1a (Fig. I-K) antibodies were expressed in the nucleus and cytoplasm of the Langerhans-like cells, especially around blood vessels in the red pulp tissue.

The histological and electron microscope studies undertaken in this investigation showed many morphological features not described previously in the African catfish spleen. It has been previously reported that the spleen of the ray-finned fish (*Barbus pectoralis*) has a one layer thick capsule comprising of an epithelium of squamous to cuboidal cells with some small round secretory cells^[19], our study has shown that the connective tissue capsule was mainly comprised from collagen fibers in the catfish. It has been also shown that the thin fibrous capsule showed little evidence of contractile ability^[20], our study confirmed that no muscle cells could be recognized in catfish spleen, adding to the theory that contractility is unlikely.

The white pulp within the spleen in our catfish showed a nodular arrangement with melanomacrophage centers, lymphocytes and surrounding arterial vessels. While in the ray-finned fish a lymphatic nodule was described, like that of mammals with germinal nodes^[19], this was absent in the present catfish study. The melanomacrophage centers have been described as ‘groupings of cells containing pigments that are generally found inside the endothelial reticulum of the matrix of hematopoietic cells in teleost fish’ but that have also been shown to be present in the brain, gonads and gills^[21]. Our study confirms the existence of these cells within the spleen of catfish and this opens up theories as to why they are present.

Several studies have suggested that these melanomacrophage centers function to destroy, detoxify or recycle endogenous and exogenous substances^{[22][23]}, which includes material produced by erythrocytes and other cells undergoing metabolic activities^{[24][25][5]}. Also it has been shown that melanomacrophage centers respond to infectious agents and other bodies, thus contributing towards immune reactions^[26].

In our study, the African catfish spleen also contained red pulp which contained sinusoids, capillaries and splenic cords of erythrocytes, in addition to macrophages and lymphocytes. This has been observed in other species such as the ray-finned fish whereby the red pulp fills the majority of the spleen and itself contained red blood cell filled sinusoids with trabeculae and lymphatic tissue diffused throughout the red pulp^[19]. In addition, also ellipsoid capillary branches, unlike mammals, were found. The ellipsoids are terminations of arterioles running through a sheath of reticular fibers, reticular cells and macrophages and have narrow lumens^[19]. It has been shown that these vessels trap blood born substances and filter plasma and therefore play an important role in immunity^{[27][6]}.

In this study, Langerhans-like cells were observed by transmission electron microscope among the cells of spleen of catfish (*Clarias gariepinus*), they were irregular to ovoid in shape and no cytoplasmic processes could be observed. This finding was in agreement with published works^[14] which also showed that Langerhans-like cells (dendritic cells) did not possess dendritic processes. In contrast, it has been shown that Langerhans-like cells in all *Actinopterygii* species (ray-finned fish) demonstrated adherent-like junctions and were in close contact with neighbouring cells^[28]. These junctions were not observed in the spleen of catfish in the present study. The previous study in ray-

finned fish added that, cytoplasmic multivesicular bodies existed within the cells and that the plasma membrane was associated with large aggregates of exosomes, indicating that they could be released/exported from the cell^[28]. These characteristics were also absent in catfish in the present study, as the cytoplasmic contents consisted of rough endoplasmic reticulum, free ribosomes and lysosomes, suggesting that there were no secretory functions in Langerhans-like cells in the catfish spleen.

Despite Langerhans cells being relatively specific to epidermal tissues and some mucosal lined organs^{[10][29][30]}, these cells were present in healthy spleen/kidney tissues and diseased gills in salmonids^{[13][14]}. Birbeck-like granules have been observed previously in salmonids within cells resembling Langerhans cells and the earliest vertebrate with an adaptive immune response are fish and therefore would require dendritic cells for antigen presentation^[28]. Our study showed that, the cytoplasm of Langerhans-like cells in the catfish spleen was electron lucent and characterized by the presence of numerous Birbeck-like granules exhibiting several shapes, varying from oval, round, rod to racket shaped granules. Previous work in the salmonids has shown that the Birbeck-like granules had a vacuolated portion and a rod section giving an overall racket shape^[14] but that fine ultrastructural differences were noted between the species overall. Three types of Birbeck-like like granules were identified in our study, the first type had heterogenic content, the second type were cored granules, the third type were racket shaped granules. Some of the racket shaped granules were enlarged having granular contents. Previous studies have also indicated that Birbeck granules are only found in Langerhans cells and not in other dendritic cells^{[10][31]}.

Previous studies have shown that Langerhans cells in the skin were positive for both CD1a and S100, dendritic cells can also be positive for both proteins but that interdigitating cells are S100 positive and CD1a negative^[15]. Although the morphological observations and presence of Birbeck-like granules indicated that the cells present in the spleen were Langerhans cells, our immunohistochemical observations showing positive staining for CD1a and S100 antibodies further confirmed the presence of Langerhans-like cells in the spleen of African cat fish and showed the locations of the cells throughout the organ. There were also similarities between the ultrastructure of the salmonids and catfish but that some granules were morphologically different between the two species.

Conclusions

The present study aimed to identify whether Langerhans-like cells were present in the African catfish spleen in order to further understand why these fish are especially resistant to disease^[4]. The cells in the present study immunostained for both S100 and CD1a indicating that the cells were Langerhans-like cells. The immunohistochemical results support the transmission electron microscopy which found that the morphology and presence of Birbeck's granules confirmed Langerhans-like cell attributes within the spleen of the catfish. This adds to the evidence that not only are Langerhans-like cells present in the epidermis and in the mucosal lining of organs including the stomach, cervix, vagina and oesophagus^{[10][29][30]}, but that they are found within the spleen of ray-finned fish^[28] and now the African catfish.

Limitations

The present study investigates the African catfish, further investigation is required in order to understand whether all fish contain a similar structure and cells within their spleens. In addition the fish sampled were adults (6-8 months old), therefore it was of interest to know when the fish develop these structures and cells and indeed how many cells and granules would be present within the organ at differing developmental stages.

Conjectures

Understanding the immune systems of the African catfish and other fish is essential for aquaculture health and welfare. Further investigations into the function of the Langerhans-like cells could help elucidate why some fish are more resistant to disease than others. Understanding the immune functions of fish can further improve not only the economic side of aquaculture, but also help to support food security.

Methods

Sample collection and ethics:

Eight healthy adult African catfish (*Clarias gariepinus*; male and female) were collected from a local fisher hatchery and humanely slaughtered. This was carried out with ethical permission (see ethics statement for further details).

General histology and light microscopy:

1 mm³ pieces of adult African catfish (n=8, aged 6-8 months, all between 2-3 kg in weight) were extracted in a systematic random manner from each spleen ensuring that differing areas of the spleen were sampled. Tissue was fixed in 10% neutral buffered formalin for 48 h then dehydrated through ascending grades of ethyl alcohol. Samples were cleared in xylene, went through three changes of liquid paraffin and embedded in paraffin blocks. Tissue sections were cut at 4 µm thick, stained using a Harris haematoxylin and eosin stain (H&E) protocol^[32] and analysed and photographed using a light microscope (Optika, B-350). Photographs were taken using systematic random sampling thus ensuring that photomicrographs did not overlap^[33], a minimum of eight photomicrographs throughout each spleen were assessed histologically from each 1 mm³ sample.

Transmission electron microscopy:

1 mm³ extracts of spleen of adult catfish (*Clarias gariepinus*) were immediately fixed in a 6% solution of phosphate-buffered glutaraldehyde, pH 7.4, at 4°C for 6 h^[34]. After initial fixation, tissues were washed in several changes of cold (4°C) 0.1 M phosphate buffer every 15 min for 2 h. Samples were then rapidly dehydrated through increasing concentrations of ethanol, transferred to propylene oxide and placed over-night in a 1:1 mixture of propylene oxide and epoxy araldite. Semi-thin sections (1 µm) were cut and stained with toluidine blue and viewed under a light microscope in order to specify areas suitable for transmission electron microscopy. Ultrathin sections (60-100 nm) were then cut using a glass knife with an ultramicrotome (Leica Biosystems) and stained with uranyl acetate followed by lead citrate^[35]. The ultrathin sections were examined with a Jeol transmission electron microscope operating at 100 Kv.

Immunohistochemistry:

Identification of Langerhans cells may be done by routine haematoxylin and eosin histological observation alone by recognising their morphological features including Birbeck granules. In order to further classify and identify Langerhans cells, CD1a and S100 immunohistochemical studies were also undertaken. Paraffin sections of 5 µm thickness were prepared on positively charged microscope slides. Murine skin sections were used as a positive control for both antibodies. Sections were deparaffinized in xylene, rehydrated in descending grades of ethanol followed by dH₂O and rinsed in phosphate buffered saline. In brief, the samples underwent peroxidase block for 5

min followed by antigen retrieval which was carried out by heating the tissue sections in 10 mM citrate buffer, pH 6.0 for 10 min followed by cooling at room temperature for 20 min. A protein block was applied prior to primary antibody incubation for 30 min at a 1:100 concentration. Monoclonal mouse anti-human CD1a antibody (Clone 010 product number IR069, Dako Agilent Technologies (Dako (2012). FLEX Ready-to-Use: Atlas of Stains, Agilent Technologies) and on separate sections a polyclonal rabbit anti-S100 antibody (product code IR504; Dako Agilent Technologies). A secondary antibody appropriate to each primary antibody was applied for 30 mins, followed by a polymer and DAB chromagen prior to counterstaining with haematoxylin, dehydration and a coverslip applied. Slide analysis and image acquisition were carried out on a light microscope and camera.

Funding Statement

The authors would like to thank Alexandria University and The University of Nottingham, School of Veterinary Medicine and Science for funding this work.

Acknowledgements


We appreciate the expertise of the staff from the Electron Microscope Unit, Faculty of Science, Alexandria University.











Ethics Statement











Eight healthy adult African catfish (*Clarias gariepinus*; male and female) were collected from a local fisher hatchery and humanely slaughtered. This was carried out with ethical permission from both the Faculty of Veterinary Medicine, Alexandria University and The School of Veterinary Medicine and Science, University of Nottingham in accordance to local, institutional and national ethics regulations (ethics number 1931 170110).










No fraudulence is committed in performing these experiments or during processing of the data. We understand that in the case of fraudulence, the study can be retracted by Matters.


References

1. Fao
Food and Agriculture Organization of the United Nations: *Clarias gariepinus*.
2014 
2. Abu Elenien, S.M., El Said H, N., Fattouh, Sh.

- Economic and Social Importance of Expanding the Production and Processing of Catfish in Egypt
World Journal of Fish and Marine Sciences, 1/2009, pages 255-261 
3. Niof
National Institute of Oceanography and Fisheries, Egypt Proposal For the Projects of Low Income
2007 
4. Hassan, I.M.
Fish Technology
2003 
5. Agius, C., Roberts, R. J.
Melano-macrophage centres and their role in fish pathology
Journal of Fish Diseases, 26/2003, pages 499-509 
6. Press C.McL., Dannevig B.H., Landsverk T.
Immune and enzyme histochemical phenotypes of lymphoid and nonlymphoid cells within the spleen and head kidney of Atlantic salmon (*Salmo salar* L.)
Fish & Shellfish Immunology, 4/1994, pages 79-93 DOI: [10.1006/fsim.1994.1007](https://doi.org/10.1006/fsim.1994.1007)

7. Steinman, R. M.
Some interfaces of dendritic cell biology
Apmis, 111/2003, pages 675-697 
8. Steinman, R.M., Hemmi, H.
Dendritic cells: translating innate to adaptive immunity.
Innate Immunity to Immunological Memory. eds Pulendran, B., and R. Ahmed,,
311/2006, pages 17-58 
9. Merad, M., Ginhoux, F., Collin, M.
Origin, homeostasis and function of Langerhans cells and other langerin-expressing dendritic cells
Nature Reviews Immunology, 8/2008, pages 935-947 
10. Birbeck, M. S., Breathnach, A. S., Everall, J. D.
An Electron Microscope Study of Basal Melanocytes and High-Level Clear Cells (Langerhans Cells) in Vitiligo
Journal of Investigative Dermatology, 37/1961, pages 51-63 
11. Wolff, K.
Fine Structure of Langerhans Cell Granule
Journal of Cell Biology, 35/1967, pages 468-473 
12. Bobryshev, Y. V., Ikezawa, T., Watanabe, T.

- Formation of Birbeck granule-like structures in vascular dendritic cells in human atherosclerotic aorta - Lag-antibody to epidermal Langerhans cells recognizes cells in the aortic wall
Atherosclerosis, 133/1997, pages 193-202 
13. Low, J., Wright, G. M., Speare, D. J.
Morphological presentation of a dendritic-like cell within the gills of chinook salmon infected with *Loma salmonae*
Developmental and Comparative Immunology, 30/2006, pages 259-263 
14. Low, J., Wright, G. M., Speare, D. J.
Comparative cellular morphology suggesting the existence of resident dendritic cells within immune organs of salmonids
Anatomical Record-Advances in Integrative Anatomy and Evolutionary Biology, 291/2008, pages 456-462 
15. Shinzato, M., Shamoto, M., Hosokawa, S., ... , Yoshida, A.
Differentiation of Langerhans Cells from Interdigitating Cells Using Cd1a and S-100 Protein Antibodies
Biotechnic & Histochemistry, 70/1995, pages 114-118 
16. L. Olga, Teruya-Feldstein Julie, Sanchez-Sos Sergio
Skin Biopsy Diagnosis of Langerhans Cell Neoplasms
Skin Biopsy - Diagnosis and Treatment, 2013 DOI: [10.5772/55893](https://doi.org/10.5772/55893) 
17. Romero-Palomo, F., Risalde, M. A., Molina, V., ... , Gomez-Villamandos, J. C.
Immunohistochemical Detection of Dendritic Cell Markers in Cattle
Veterinary Pathology, 50/2013, pages 1099-1108 
18. Park, H. J., Jeon, Y. K., Lee, A. H., ... , Jung, K. C.
Use of the JL1 Epitope, Which Encompasses the Nonglycosylation Site of CD43, as a Marker of Immature/Neoplastic Langerhans Cells
American Journal of Surgical Pathology, 36/2012, pages 1150-1157 
19. Mahabady, M., Morowati, H., Arefi, A., Karamifar, M.
Anatomical and histomorphological study of spleen and pancreas in berzem (*barbus pectoralis*).
World J. Fish Mar. Sci. , 4/2012, pages 263-267 
20. Genten, F., Terwinghe, E., Danguy, A.
Atlas of Fish Histology
2009 
21. Macchi, G. J., Romanol, A., Christiansen, H.E.
Melanomacrophage centers in white mouth croaker *Micropogonias furneyi*, as biological indicators of environmental changes.
J. Fish Biol., 40/1992, pages 971-97 

22. Ferguson, H. W.
Relationship between Ellipsoids and Melano-Macrophage Centers in Spleen of Turbot (Scophthalmus-Maximus)
Journal of Comparative Pathology, 86/1976, pages 377-380 
23. Herraez, M. P., Zapata, A. G.
Structure and Function of the Melanomacrophage Centers of the Goldfish Carassius-Auratus
Veterinary Immunology and Immunopathology, 12/1986, pages 117-126 
24. Roberts, T. R.
Geographical Distribution of African Freshwater Fishes
Zoological Journal of the Linnean Society, 57/1975, pages 249-319 
25. Fulop, G. M. I., McMillan, D. B.
Phagocytosis in the Spleen of the Sunfish Lepomis Spp
Journal of Morphology, 179/1984, pages 175-195 
26. Ellis A. E., de Sousa Maria
Phylogeny of the lymphoid system. I. A study of the fate of circulating lymphocytes in plaice
European Journal of Immunology, 4/1974, pages 338-343 [DOI: 10.1002/eji.1830040505](https://doi.org/10.1002/eji.1830040505) 
27. Ellis, A.E., Roberts, R.J., Tytler, P.
The anatomy and physiology of teleosts.
1989, pages 13-55 
28. Lowy, J., Wright, G. M., Speare, D. J., ... , Dykova, I.
Comparative Ultrastructure of Langerhans-Like Cells in Spleens of Ray-Finned Fishes (Actinopterygii)
Journal of Morphology, 271/2010, pages 1229-1239 
29. Bock, P.
Fine-Structure of Langerhans Cells in Stratified Epithelia of Esophagus and Stomach of Mice
Zeitschrift Fur Zellforschung Und Mikroskopische Anatomie, 147/1974, pages 237-247 
30. Hussain, L. A., Lehner, T.
Comparative Investigation of Langerhans Cells and Potential Receptors for Hiv in Oral, Genitourinary and Rectal Epithelia
Immunology, 85/1995, pages 475-484 
31. Mc Dermott, R., Ziylan, U., Spehner, D., ... , Hanau, D.
Birbeck granules are subdomains of endosomal recycling compartment in human epidermal Langerhans cells, which form where Langerin accumulates

Mol Biol Cell, 13/2002, pages 317-35 

32. Harris, H.F.

The haematoxylin.

Theory and Practice of Histological Techniques, 1900, pages 405-415 

33. Mayhew Tm

The new stereological methods for interpreting functional morphology from slices of cells and organs

Experimental Physiology, 76/1991, pages 639-665 DOI:

[10.1113/expphysiol.1991.sp003533](https://doi.org/10.1113/expphysiol.1991.sp003533) 

34. McDowell, E. M., Trump, B. F.

Histologic Fixatives Suitable for Diagnostic Light and Electron-Microscopy

Archives of Pathology & Laboratory Medicine, 100/1976, pages 405-414 

35. Hayat, M.

Basic techniques for transmission Electron Microscope

1986 

Comments

[Create a Matters account](#) to leave a comment.